



PATIENT PRESENTING CLINICAL SIGNS

Lola Pagon Grade 4/6 murmur, clinically asymptomatic
Meds pimo 2.5mg 1/2 bid

SPECIES ULTRASONOGRAPHIC EXAMINATION OF THE HEART

Canine

BREED
Pekingese

SEX
FS

AGE
11yr

WEIGHT
3.7kg

CANINE CARDIAC PARAMETERS	MR VMAX (m/s)	TR VMAX (m/s)	LA/AO M-mode	LA/AO (Heart Base; Swe)	FS (%)	EF (%)	EPSS (cm)
NORMAL PARAMETER	4.5-5.5	<2.7	1.3	Up to 1.6	28-40	40-100	<0.6
PATIENT	5.5	--	--	1.6	45	78	0.1
CANINE CARDIAC PARAMETERS	HR (BPM)	AV VMAX (m/s)	PV MAX (m/s)	BODY WEIGHT	LAD LA MAX 4 Chamber	LVIDd Avg; 2D and m-mode short axis (cm)	LVIDs Avg; 2D and m-mode short axis (cm)
NORMAL PARAMETER	50-100	0.7-1.7	0.7-1.6				
PATIENT	NM	1.4	1.0	3.7kg	2.9	2.8	--

Cardiac Presentation

The echocardiogram in this patient demonstrated mild increased left atrial size based on 2 different LA measurement methods. Mild interatrial septal deviation. The cranial and caudal mitral valve leaflets presented thickening consistent with endocardiosis with mild valve prolapse. Doppler indicated measurable significant eccentric insufficiency. The left ventricle presented mild increased dimension. The myocardium presented normal echogenicity without subjective evidence of significant fibrotic or ischemic disease. Contractility of the ventricular walls was adequate and in normal range for this patient evidenced by the fractional shortening measurement and subjective evaluation of the different regions of the myocardium. The left ventricular outflow tract demonstrated normal laminar flow and subjective structural integrity. The right atrium and auricle revealed normal size, structure and content. No evidence of masses was noted or chamber overload. Tricuspid valvular assessment demonstrated adequate linear morphology. The right ventricle was of normal size (1/3 diameter of LV), chordae structure, myocardial echogenicity and thickness. Pulmonic tract assessment revealed normal valve structure, laminar flow, and diameter (approx.1:1 pa/ao ratio). No visible pericardial or free pleura fluid was noted. No echographically detectable evidence of cardiac / pericardial tumors was visible.

INTERPRETED BY

R. McKenzie Daniel, DVM, DABVP (Canine and Feline)

IMAGING PERFORMED BY

Kerri Becker

HOSPITAL NAME

Bond Vet Montclair

REFERRING VET

Dr Sposato

INVOICE
24445

DATE
04/10/2026

ULTRASONOGRAPHIC FINDINGS

Primary

- Chronic mitral valve disease with mild valve prolapse (ACVIM B2)

INTERPRETATION OF THE FINDINGS & FURTHER RECOMMENDATIONS



PATIENT

Lola Pagon

SPECIES

Canine

BREED

Pekingese

SEX

FS

AGE

11yr

WEIGHT

3.7kg

INTERPRETED BY

R. McKenzie Daniel,
 DVM, DABVP
 (Canine and Feline)

IMAGING PERFORMED BY

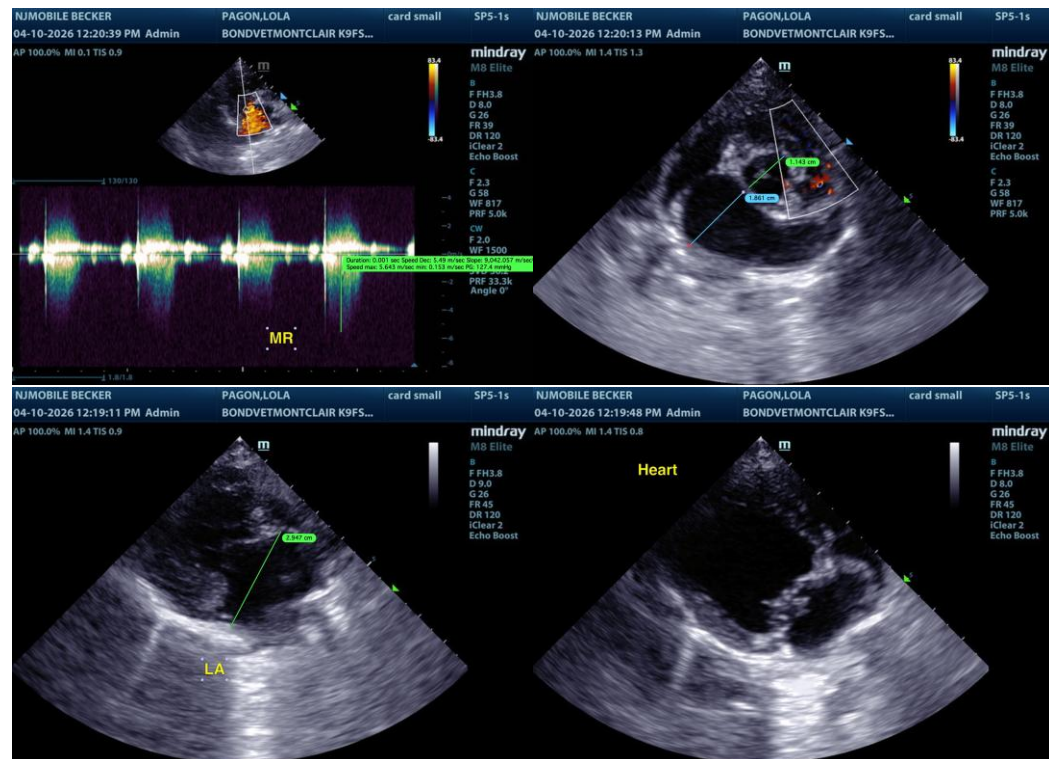
Kerri Becker

HOSPITAL NAME

Bond Vet Montclair

The cause of the murmur is chronic degenerative valvular changes with secondary eccentric mitral valve insufficiency. The left atrial enlargement implies that the risk of complication secondary to mitral valve insufficiency is elevated, yet overall, the heart appears stable. No other clinical issues such as LV systolic dysfunction or clinical pulmonary hypertension. Pimobendan 0.3 mg/kg BID is recommended. No overt indication for additional medication. Prognosis is considered variable and sonographic monitoring is recommended. Recheck echo cardiogram is suggested in 6 months, sooner if clinical signs arise.

Anesthetic risk is considered mild to moderate yet likely mildly reduced once on Pimobendan for 3-5 days. If required, the following protocol is recommended with judicious IV fluid administration. Suggested anesthetic protocol may include opioid or Benzodiazepine pre-med, induction with Propofol or Alfaxalone, and appropriate gas anesthesia with avoidance of alpha 2 agonists.



REFERRING VET

Dr Sposato

INVOICE
 24445

DATE
 04/10/2026

The information and recommendations provided are based on the images presented by the referring veterinarian/sonographer. No evaluation can be communicated regarding pathology that was not visible in the image/video clips provided.

Thank you for this referral. If the clinical or image interpretation does not parallel your findings or if I can be of any further assistance, please contact me.



PATIENT

Lola Pagon

R. McKenzie Daniel, DVM, DABVP (Canine/Feline Practice)

info@sonopath.com

SPECIES

Canine

BREED

Pekingese

SEX

FS

AGE

11yr

WEIGHT

3.7kg

INTERPRETED BY

R. McKenzie Daniel,
DVM, DABVP
(Canine and Feline)

**IMAGING
PERFORMED BY**

Kerri Becker

HOSPITAL NAME

Bond Vet Montclair

REFERRING VET

Dr Sposato

**INVOICE
24445**

DATE
04/10/2026